



PATIENT

Little Bit Hood

SPECIES

Canine

BREED

Yorkshire Terrier

SEX

Female Spayed

AGE

9 years

WEIGHT

10lbs

INTERPRETED BY

Maggie Machen Lamy,
DVM, DACVIM
(Cardiology)

IMAGING PERFORMED BY

Sarah Pender, CVT

HOSPITAL NAME

SVS Imaging QC

REFERRING VET

Dr. Trammell

INVOICE

27601

DATE

11/21/22

PRESENTING CLINICAL SIGNS

History: Presented for persistent coughing following dental with 1 extraction. Was started on oral furosemide; reported significant improvement of coughing. Progressive heart murmur, now grade 4/6. -Radiographs: Revealed cardiomegaly and suspected cardiogenic pulmonary edema.

RADIOGRAPHIC FINDINGS *NOTE: Images submitted for supplemental cardiac information only. Mild cardiomegaly. No obvious evidence of CHF.

ELECTROCARDIOGRAPHIC FINDINGS *Note: Single lead ECGs are evaluated as a rhythm strip. Morphology/MEA cannot be definitively commented on.

A single lead ECG is available; 25mm/s, 10mm/mV. The average heart rate is 130bpm with a largely regular rhythm. The rhythm is sinus in origin, with a p for every QRS complex and vice versa. The P and QRS morphologies are positive. No ectopic beats, pauses or other dysrhythmias observed.

ECG diagnosis: Normal sinus rhythm with respiratory variation.

ECHOCARDIOGRAM FINDINGS

2D, m-mode and Doppler imaging are available. Diffuse thickening of mitral valve leaflets (anterior > posterior) with prolapse into the left atrial lumen. Severe eccentric mitral regurgitation with severe left atrial dilation. Significant LV dilation with hyperdynamic myocardial function. The tricuspid valve appears mildly thickened, with mild tricuspid regurgitation. Mildly elevated velocity. Mild right atrial and ventricular dilation consistent with early pulmonary arterial hypertension. The pulmonic and aortic valves are normal in morphology and mobility. Normal pulmonic and aortic outflow velocities. No pulmonic or aortic insufficiency. No pericardial or pleural effusion noted. No cardiac tumors observed.

CARDIAC CHART

CANINE CARDIAC PARAMETERS	MR VMAX (m/s)	TR VMAX (m/s)	LA/AO (Boon method)	LA/AO (Heart Base; Swe)	FS (%)	EF (%)	EPSS (cm)
NORMAL PARAMETER	4.5-5.5	<2.7	1.3	<1.6	28-40	40-100	<0.6
PATIENT	4.8	2.9	NM	2.5	44	77	0.27
CANINE CARDIAC PARAMETERS	HR (BPM)	AV VMAX (m/s)	PV MAX (m/s)	BODY WEIGHT (kg)	LA 2D short axis Base view (cm)	LVIDd Avg; 2D and m-mode short axis (cm)	LVIDs Avg; 2D and m-mode short axis (cm)
NORMAL PARAMETER	50-100	0.7-1.7	0.7-1.6	BELOW	BELOW	BELOW	BELOW
PATIENT	110	1.1	0.7	4.5	2.7	3.3	1.8
*Normal chamber parameters expressed as a mean value (SD)				3	1.27 (5.3)	2.46 (2.46)	1.36 (5.5)
BODY WEIGHT DEPENDENT PARAMETERS				5	1.40 (4.5)	2.74 (5.2)	1.60 (4.7)
*Note: All measurements based upon multi-modal images and methods. An average value is reported.				10	1.50 (3.8)	3.27 (3.5)	2.06 (3.1)
				15	1.83 (2.0)	3.71 (2.4)	2.43 (2.1)
				20	2.02 (1.9)	4.14 (2.2)	2.80 (2.0)
				25	2.18 (2.4)	4.48 (2.9)	3.10 (2.5)
				30	2.33 (3.3)	4.83 (3.9)	3.39 (3.4)
				35	2.48 (4.3)	5.17 (5.0)	3.69 (4.5)
				40	2.62 (5.2)	5.48 (6.1)	3.96 (5.4)

Adapted from June Boon, Veterinary Echocardiography, 1998
Rishniw M and Hollis NE, J Vet Intern Med 2000; 14:429-435
Hansson et al, Vet Rad and Ultrasound 2002
Bonagura et al. Echocardiography: principles of interpretation, Vet Clin North Am 15:1177, 1995



PATIENT

	50	2.88 (7.1)	6.07 (8.3)	4.46 (7.4)
--	----	------------	------------	------------

Little Bit Hood

SPECIES

Canine

BREED

Yorkshire Terrier

SEX

Female Spayed

AGE

9 years

WEIGHT

10lbs

INTERPRETED BY

Maggie Machen Lamy,
DVM, DACVIM
(Cardiology)

IMAGING PERFORMED BY

Sarah Pender, CVT

HOSPITAL NAME

SVS Imaging QC

REFERRING VET

Dr. Trammell

INVOICE

27601

DATE

11/21/22

INTERPRETATION OF THE FINDINGS & FURTHER RECOMMENDATIONS

The cause of the murmur is chronic degenerative valve disease causing severe mitral and mild tricuspid regurgitation. Severe left atrial enlargement indicates the risk for spontaneous congestive heart failure is elevated. Mild TR is also noted, with evidence of early pulmonary hypertension. No additional issues such as systolic dysfunction are identified and the ECG is unremarkable.

The described cough is likely multi-factorial in origin, including a mechanical component due to cardiomegaly, possible concurrent airway disease and/or early CHF given the severity of disease. Screening chest radiographs do not show overt CHF; however, given the symptoms, response to lasix and echo findings, full lifelong **cardiac support is recommended as below** including Lasix therapy. Depending on clinical response to the medications, cough suppression may also be useful. **Monitoring of sleeping breathing rates in the future will be paramount to determine the origin of any future cough.** The average survival of canine patients with active pulmonary edema is 8-9 months on medications, however they generally are able to maintain a good quality of life for that period. Patient will always be at risk for recurrent CHF, development of arrhythmias/LA tear, syncope and/or sudden death in the future. Monitoring of renal values is recommended lifelong.

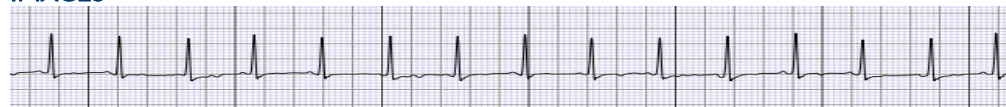Omega fatty acid supplementation and mild salt restriction may also be of some long term benefit. Monitor for development of a worsening cough, labored breathing, exercise intolerance or collapse episodes.

Plan: Screening BP and CXR recommended. Administer Pimobendan 0.3mg/kg PO q12h. Administer low dose furosemide/Lasix 1 mg/kg PO q12h. Administer spironolactone 1-2mg/kg PO q12h. Consider hydrocodone with homatropine (0.2-0.4mg/kg PO up to q4-6 hours PRN) if cough persists despite normal SRRs.

A renal panel and BP are recommended in 10-14 days, then every 3-4 months on diuretics to ensure tolerance of medications. If doing well at that time and BP >130mmHg, institute ACEI 0.5mg/kg PO q12h.

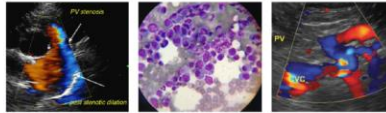
A recheck echocardiogram is recommended in 6 months to screen for progression, sooner if clinical signs arise/persist.

IMAGES



IMAGING PERFORMED BY

svsmobileimaging.com 309 - 737 - 3070



Clinical Sonography & Telecytology

EDUCATIONAL TELECONSULTATION SERVICES™

1-800-838-4268 info@sonopath.com SonoPath.com

PATIENT

Little Bit Hood

SPECIES

Canine

BREED

Yorkshire Terrier

SEX

Female Spayed

AGE

9 years

WEIGHT

10lbs

INTERPRETED BY

Maggie Machen Lamy,
DVM, DACVIM
(Cardiology)

IMAGING PERFORMED BY

Sarah Pender, CVT

HOSPITAL NAME

SVS Imaging QC

REFERRING VET

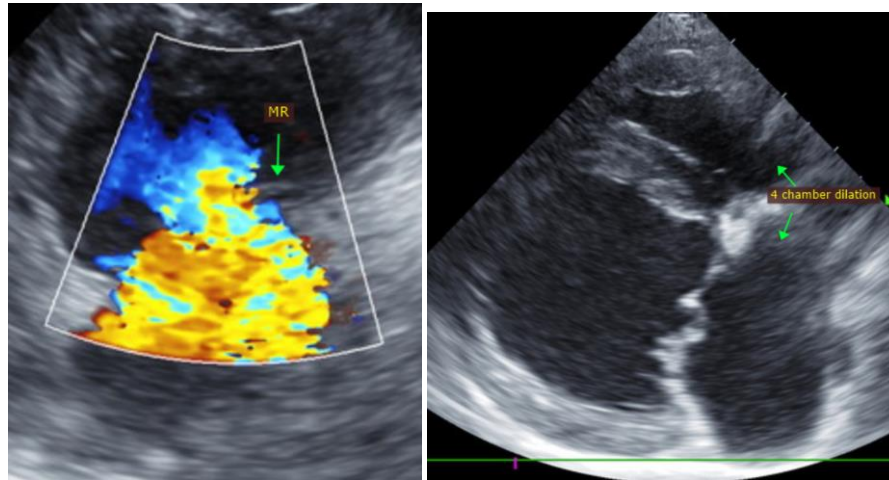
Dr. Trammell

INVOICE

27601

DATE

11/21/22



The information and recommendations provided are based on the images presented by the referring veterinarian. No evaluation can be communicated regarding pathology that was not visible in the image/video clips provided.

Thank you for this referral. If the clinical or image interpretation does not parallel your findings or if I can be of any further assistance, please contact me.

Maggie Machen Lamy, DVM
Diplomate of the American College of Veterinary Internal Medicine (Cardiology)
info@sonopath.com